

PATIENT PRESENTING CLINICAL SIGNS

Diesel Muschlitz History: ADR, intermittent vomiting, weight loss, anorexia, inappropriate urination, UTD lepto, 1/6 murmur

SPECIES

Canine

ECHOCARDIOGRAPHIC FINDINGS

2D, M-mode, Doppler study. This exam is compared to the one performed 6/28/21.

BREED

Boxer

Left atrial size is normal. The mitral valve leaflets are very mildly thickened, and a very mild jet of mitral regurgitation is present. Left ventricular dimensions are normal, as is left ventricular systolic function. The aorta and aortic valve appear normal, though there is mildly increased flow velocity in the ascending aorta. Right atrial and right ventricular dimensions are normal. The tricuspid valve is normal. The pulmonary artery and pulmonic valve are normal. No pericardial effusion or cardiac masses are seen.

SEX

Male Neutered

AGE

5 years
LA – 35.2 mm (prev. 37.3 mm)
LVIDd – 35.2 mm (prev. 39.3 mm)
LVIDs – 25.6 mm (prev. 26.5 mm)
FS – 27.3% (prev. 32.6%)

WEIGHT

76 lbs

ASSESSMENT/RECOMMENDATIONS

Degenerative mitral valve disease

INTERPRETED BY

Keith Blass, DVM,
MS, DACVIM

This examination is very similar to the one performed 3.5 months ago, and shows no progression of Diesel's mitral valve disease. As such, his disease still appears to be well-compensated, and it does not appear to be contributing to Diesel's clinical signs.

IMAGING PERFORMED BY

Rebekah Jakum, CVT
ARDMS/RVT

No therapy is recommended based on this exam.

A recheck echocardiogram is recommended in 9 months to monitor for disease progression.

HOSPITAL NAME

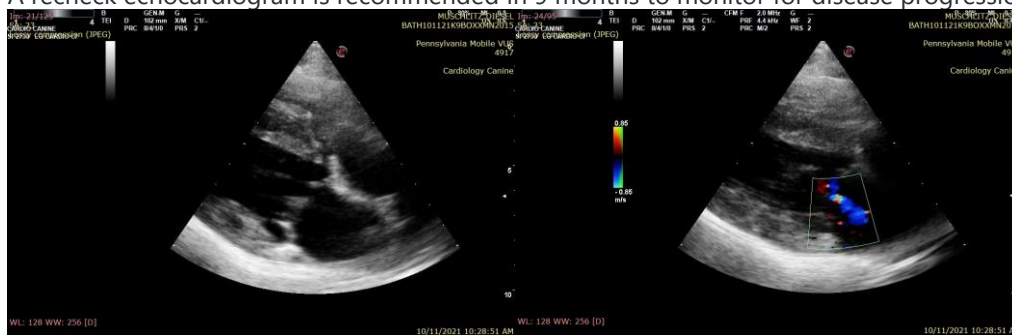Lehigh Valley AH
(Bath)

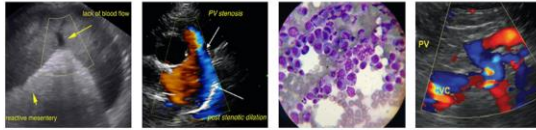
REFERRING VET

Dr. Tan

DATE

10.11.2021





PATIENT

Diesel Muschlitz

The information and recommendations provided are based on the images presented by the referring veterinarian. No evaluation can be communicated regarding pathology that was not visible in the image/video clips provided.

SPECIES

Canine

Thank you for this referral. If the clinical or image interpretation does not parallel your findings or if I can be of any further assistance please contact me.

BREED

Boxer

Keith Blass, DVM, MS, DACVIM (Cardiology)

KeithBlass@gmail.com
631-804-5754

SEX

Male Neutered

AGE

5 years

WEIGHT

76 lbs

INTERPRETED BY

Keith Blass, DVM,
MS, DACVIM

**IMAGING
PERFORMED BY**

Rebekah Jakum, CVT
ARDMS/RVT

HOSPITAL NAME

Lehigh Valley AH
(Bath)

REFERRING VET

Dr. Tan

DATE

10.11.2021